

# Orthodontic tooth movement after periodontal regeneration of intrabony defects

Conchita Martin<sup>a,b</sup>   
Mariano Sanz<sup>a,c</sup> 

<sup>a</sup>Section of Orthodontics, Department of Dental Clinical Specialties, Complutense University of Madrid, Madrid, Spain

<sup>b</sup>BIOCRAN (Craniofacial Biology: Orthodontics and Dentofacial Orthopedics) Research Group, Complutense University of Madrid, Madrid, Spain

<sup>c</sup>ETEP (Etiology and Therapy of Periodontal and Peri-implant Diseases) Research Group, Complutense University of Madrid, Madrid, Spain

The prevalence of intrabony defects in patients with advanced periodontitis stages III and IV is high. These patients usually need both periodontal treatment and orthodontic therapy, including tooth movement through bone defects, to improve masticatory function, aesthetics, and overall quality of life. Clinical practice guidelines recommend periodontal regenerative surgical interventions to resolve these defects and propose initiating orthodontic tooth movement (OTM) once periodontal therapy goals have been met. Surgical interventions using various regenerative technologies like barrier membranes and enamel matrix proteins, combined or not with bone replacement grafts, have proven effective in regenerating lost periodontal tissues. However, the combination of periodontal and orthodontic treatments requires consideration of how periodontal regenerative therapies influence OTM. Studies suggest that regenerated bone may differ in density, composition, vascularity, and cellular activity, potentially affecting the speed and efficiency of OTM, and potential root resorption of moved teeth. Understanding the sequence and timing of implementing OTM after regenerative periodontal interventions is crucial due to their interlinked processes of bone resorption and formation. This narrative review aims to uncover scientific evidence regarding these combined treatments, examining the impacts of different regenerative technologies on OTM and delineating their advantages, limitations, and best practices.

**Key words:** Tooth movement, Periodontal surgery, Intrabony defect, Regenerative surgery

Received January 15, 2024; Accepted January 16, 2024.

**Corresponding author:** Conchita Martin.

Professor, Section of Orthodontics, Department of Dental Clinical Specialties, Complutense University of Madrid, Plaza Ramón y Cajal, s/n, Madrid 28040, Spain.

**Tel** +34-3941964 **e-mail** mariacom@ucm.es

**How to cite this article:** Martin C, Sanz M. Orthodontic tooth movement after periodontal regeneration of intrabony defects. Korean J Orthod 2024;54(1):3-15. <https://doi.org/10.4041/kjod24.007>

© 2024 The Korean Association of Orthodontists.

This is an Open Access article distributed under the terms of the Creative Commons Attribution Non-Commercial License (<http://creativecommons.org/licenses/by-nc/4.0>) which permits unrestricted non-commercial use, distribution, and reproduction in any medium, provided the original work is properly cited.

## INTRODUCTION

Orthodontic tooth movement (OTM) aims to correct tooth position to improve both dental occlusion and aesthetics, what positively impacts the perception of orthodontic treatment among adults.<sup>1</sup> On the other hand, patients with periodontitis, due to the frequent sequelae of this disease (periodontal attachment and tooth loss), often require inter-disciplinary treatments, including OTM, for the effective rehabilitation of the masticatory function, aesthetics and improvement of their quality of life.<sup>2</sup> This clinical scenario is frequent in patients with periodontitis stages III and IV, where the prevalence of intrabony defects is high and the need for OTM due to the pathologic tooth migration, requires the combination of periodontal regenerative treatments and orthodontic therapy.<sup>3</sup> According to the recently published clinical practice guidelines for the treatment of periodontitis stage III<sup>4</sup> and stage IV,<sup>2</sup> the treatment residual deep pockets associated with intrabony defects after the steps I and II of periodontal therapy requires further periodontal treatment, including periodontal regenerative interventions for the resolution of the intrabony defects. Similarly, the clinical practice guidelines<sup>2</sup> recommend the initiation of OTM, when indicated, once the endpoints of periodontal therapy have been achieved.

Deep intrabony defects are treated efficiently with surgical interventions,<sup>5</sup> which include the use of different regenerative technologies. The use of barrier membranes and enamel matrix proteins, either alone or combined with bone replacement grafts, have demonstrated efficacy to significantly improve periodontal attachment and bone gain in intrabony defects,<sup>6</sup> also demonstrating ability to regenerate the lost periodontal tissues by formation of new cementum, periodontal ligament, and alveolar bone, in pre-clinical *in vivo* investigations.

When combining periodontal and orthodontic treatments, it is important to understand what is the impact of the periodontal regenerative therapy and the likely influence of the different regenerative technologies used, on the OTMs. The combination of both therapies may influence the success of regenerative interventions, since OTM may enhance osteogenic activity,<sup>7</sup> but also have an impact on the dynamics of the OTM through the regenerated tissues, which may differ from conventional tooth movement in natural bone. Pre-clinical *in vivo* investigations suggest that regenerated bone may demonstrate differences in density, composition, vascularity, and cellular activity, thus affecting the speed and efficiency of OTM.<sup>8</sup> Furthermore, possible side-effects, such as root resorption, associated with the use of different biomaterials as bone-replacement graft may also negatively affect the outcome of orthodontic therapy. Another

matter of clinical relevance when undertaking combined periodontal regenerative and orthodontic treatments, is the understanding of the appropriate-preferable timing/sequence of implementing OTM after the regenerative periodontal interventions, since these movements are based on controlled processes of bone resorption/formation that may be affected by the underlying periodontal regenerative process and the influence of the regenerative technologies utilized.

It is, therefore, the purpose of this narrative review to unveil the scientific evidence behind these combined periodontal regenerative and orthodontic treatments to elucidate not only on the possible effects of the different regenerative technologies used (such as bone replacement grafts, barrier membranes or biologicals) on the OTM, but also to identify the advantages, limitations, and best practices when combining these therapies.

## REGENERATIVE TECHNOLOGIES USED FOR PROMOTING PERIODONTAL REGENERATION IN HUMAN INTRABONY DEFECTS

Two main regenerative technologies, either the use of barrier membranes, from natural or synthetic sources (guided tissue regeneration) or the application of biologicals, as the enamel matrix proteins, have demonstrated in pre-clinical *in vivo* investigations their biological ability to regenerate the periodontal tissues lost as a consequence of periodontitis,<sup>6</sup> as well as their clinical efficacy to treat periodontally affected teeth with intrabony defects.<sup>9</sup> Since these technologies do not provide a scaffold effect and hence, do not effectively maintain the space to be regenerated, they are often combined with the placement of different biomaterials as bone replacement grafts. In fact, clinical studies, have provided evidence that the combined therapy may be more efficacious in presence of the most frequent intrabony defects.<sup>10</sup>

Membranes used for periodontal regeneration, namely guided tissue regeneration (GTR), are barrier shields made of natural or alloplastic biomaterials (mainly natural porcine source) that are placed between the soft periodontal tissues and the root surface, thus isolating the defect and allowing the cells from the periodontal ligament to repopulate the wound and hence, allowing only cells with potentiality for periodontal regeneration and excluding the epithelial and connective tissue cells from the flap, from migrating into the healing area.

Growth factors and biological factors comprise different proteins with biological activities promoting periodontal regeneration. Although some autologous blood-derived products (ABPs) or recombinant human platelet-derived growth factor-BB (rhPDGF-BB) have

shown some potential in preclinical studies, their clinical efficacy is limited. Enamel matrix derivatives (EMD) obtained from porcine tooth buds are a group of proteins involved in the embryological process of root formation, which when applied on root surfaces deprived from the periodontal attachment, promote new cementum formation and new periodontal attachment and bone formation. Differently from other growth factors, EMD have shown both histological and clinical efficacy in the treatment of periodontal intrabony defects.<sup>9</sup>

Both barrier membranes and EMDs enhance the recruitment of stem cells from the defect walls, promote angiogenesis and encourage the deposition of bone matrix, thus facilitating the self-regeneration of lost or damaged bone tissue. Since these technologies enhance regeneration without the interposition of any scaffolding material, their use may facilitate OTMs, but the fact that they do not possess any space maintenance properties, may significantly limit their clinical use in presence of wide and large intrabony defects.

Both barrier membranes and biologicals are frequently used in combination with bone replacement grafts, since they provide the scaffolding effect and contribute to both mechanical support and the guidance of the regenerative process. Depending on the properties of the biomaterial used, they may provide osteoinduction and enhance new bone formation, although the majority will only provide osteoconduction, allowing bone growth through the three-dimensional structure of the graft, but without exerting any bone inductive activity. Osteoinduction, therefore involves the active differentiation of the osteoprogenitor cells into osteoblasts, mainly through the release of bone morphogenetic proteins. A recent systematic review<sup>6</sup> of human histologic studies has evaluated the potential for periodontal regeneration of the different biomaterials used as bone replacement grafts: autografts (autologous bone from the patient), allogenic bone (human bone from cadaveric sources), xenogeneic bone (natural bone of animal origin), and alloplastic (synthetic) materials.

Autografts are derived from the patient's own bone, and although considered as the gold standard grafting material, due to its biocompatibility and osteogenic potentiality, since they can demonstrate osteogenesis, osteoinduction, and osteoconduction, they are seldom used due to limitations in quantity constraints and donor site morbidity.

Allografts, being also from human source, although from genetically different individuals may share osteoinductive properties, and hence, they present a viable alternative to autografts, without restrictions due to donor site morbidity. However, potential challenges, such as the immunogenic reactions and variations in graft integration may limit their use. Freeze-dried bone

allograft (FDDBA) and decalcified freeze-dried bone allograft (DFDBA) are the two most evaluate allografts, having demonstrated osteoconductive properties based on the release of bone morphogenetic proteins (BMPs), what may enhance bone formation.

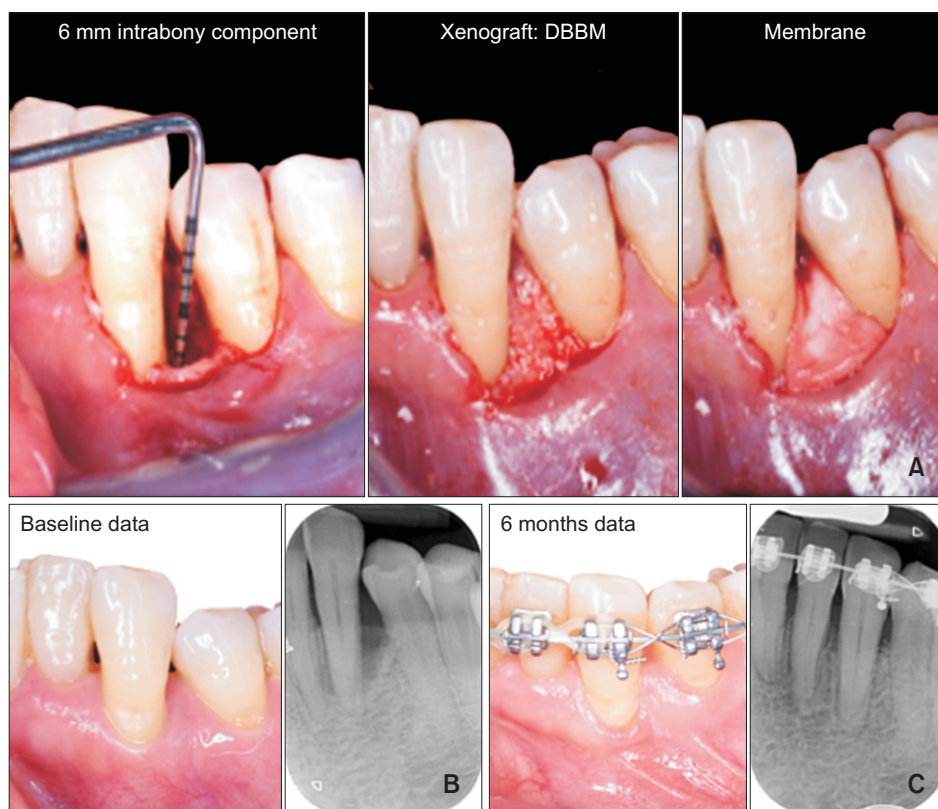
Xenografts are sourced from species genetically distinct from humans. The source most frequently used and tested is bovine, mainly deproteinized bovine bone mineral (DBBM), which has shown high biocompatibility, osteoconductivity and excellent scaffolding effect, since it has a very low degree of bioabsorbability, what may be positive as a space maintenance effect, but may potentially hinder the OTM (Figure 1).

Alloplastic materials are biomaterials made by synthesis or chemical processing. They offer advantages such as unlimited supply, no donor site morbidity, and reduced risk of disease transmission, although the biologic activity of currently used alloplastic biomaterials in periodontal regeneration is limited. These alloplasts are mainly calcium phosphates (CaP), hydroxyapatite (HA) (conventionally sintered HA or nanophase HA), beta-tricalcium phosphate ceramics ( $\beta$ -TCP), or biphasic CaP (composite of HA/ $\beta$ -TCP).

### INFLUENCE OF DIFFERENT GRAFT MATERIALS ON ORTHODONTIC TOOTH MOVEMENT: EXPERIMENTAL STUDIES

The possible effect of different bone-grafting materials used in periodontal regenerative interventions on subsequent OTM are of concern since they may affect the rate of tooth movement and potentially cause side effects, such as root resorption. The scientific evidence of this potential influence derives mainly from preclinical *in vivo* investigations and some observational clinical studies, although recently, several split-mouth randomized clinical trial (RCT) have been carried out in humans. However, these studies did not use as the site for regeneration the periodontal intrabony defect, but the fresh extraction socket.<sup>11-14</sup>

Table 1 summarizes the available evidence from preclinical *in vivo* investigations. Included investigations have been comparative studies with had at least one pair of comparisons. Most of these investigations used as animal model the dog,<sup>15-27</sup> followed by rats<sup>28-30</sup> and mice.<sup>31,32</sup> Cat,<sup>33</sup> goat,<sup>34</sup> mini-pig,<sup>35</sup> and rabbit<sup>36</sup> models have also been used for assessing OTM through regenerated bone. These preclinical investigations, although allowing for a controlled experimentation, provide limited direct translation to the human reality, not only due to species differences, but also due to very different environmental conditions. On the other hand, animal studies exhibit genetic homogeneity and controlled living conditions, thus reducing the variability in responses within



**Figure 1.** Orthodontic tooth movement through regenerated intrabony defect. **A**, Surgical procedure. **B**, Baseline data. **C**, Six months follow-up. DBBM, deproteinized bovine bone mineral.

a time frame usually much shorter. Differences in dental anatomy and physiology between species may also lead to variations in tissue responses to orthodontic forces.

An ideal pre-orthodontic regenerative technology should promote full regeneration of the lost periodontal tissues, thus providing a natural bone and periodontal ligament environment for the intended OTM, without promoting any undesirable side-effects, like root resorption. The stability during the wound healing process at the defect site and therefore, the need for a biomaterial as a bone replacement graft that provides the adequate scaffolding effect for the new bone matrix formation, may affect the dynamics of subsequent OTMs depending on its bio absorbability and potentiality for root resorption.

#### Autografts

Five studies have used autografts<sup>15,17,19,30,34</sup> from tibia or iliac bone as bone replacement grafts. One of them, in dogs,<sup>17</sup> included a negative control group, allowing for self-regeneration, and a third group combining the autograft with recombinant human bone morphogenetic protein-2 (rhBMP-2). No differences in OTM were found. Root resorption was partially observed only in the rhBMP-2 group.

Four studies, two in dogs,<sup>15,19</sup> one in rats<sup>30</sup> and one in goats,<sup>34</sup> compared the use of autografts with alloplasts.

Beta-tricalcium phosphate ceramics was used in all cases, alone, in combination with bone marrow stromal cells (bMSCs),<sup>19</sup> or combined with HA and compared with a Xenograft (of human bone, used in rats) too.<sup>30</sup> As a general outcome, augmented bone with  $\beta$ -TCP did not prevent tooth movement compared to autografts, demonstrating similar results,<sup>15,30,34</sup> although in one study the incidence of root resorption was lower in the  $\beta$ -TCP group.<sup>15</sup> Zhang et al.<sup>19</sup> found that OTM was faster in the  $\beta$ -TCP, compared to autograft, although when compared with  $\beta$ -TCP combined with bMSCs the rate of OTM was similar, as well as the root resorption, which was similar in the three groups.

Autografts generally demonstrated a lower risk of root resorption due to their higher biocompatibility and similarity to natural bone, although this outcome is also dependent on the magnitude of the orthodontic forces.

#### Allografts

Allografts have been evaluated in three studies, two using DFDBA, one in dogs<sup>20</sup> and the other in rabbits.<sup>36</sup> The third study<sup>32</sup> using femurs and tibias in mice compared allografts to alloplasts ( $\beta$ -TCP). When comparing DFDBA to negative controls in experimental defects in dogs,<sup>20</sup> there was a slight increase in OTM at grafted sites ( $P < 0.05$ ). Also, there was a significant bone resorption in the control site and successful socket pres-

Table 1. Characteristics of the pre-clinical studies

Author (yr)	Study design	Graft type	Time OTM after surgery	OTM duration	OTM difference	RR	Appliance; force applied
Sheats et al. <sup>33</sup> (1991)	Animal study (cats)	A. Alloplast: β-TCP B. Control (no graft)	6 wk	9 wk	No significant differences	NR	Niti closed_coil spring; 100 g of force
Hossain et al. <sup>15</sup> (1996)	Animal study (dogs)	A. Autograft: iliac bone B. Alloplast: β-TCP	2-4 wk	9-15 wk	Alloplast = autograft (qualitative assessment)	Autograft > alloplast	Lingual arch with open-coil spring
Araújo et al. <sup>16</sup> (2001)	Animal study (dogs)	A. Xenograft: DBBM B. Control (no graft)	12 wk	NR	No differences	No differences	sectional wire with closed coil spring; 30-50 cN of force
Kawamoto et al. <sup>17</sup> (2002)	Animal study (dogs)	A. Autograft: tibia B. rhBMP-2 with poly [D,L-(lactide-co-glycolide)] C. Control_d (defect no graft) D. Control (only extraction socket)	4 mo	2 mo	No differences (qualitative assessment)	rhBMP-2 > autograft = control_d	Niti closed_coil spring; 100 g of force
Kawamoto et al. <sup>18</sup> (2003)	Animal study (dogs)	A. rhBMP-2 with poly [D,L-(lactide-co-glycolide)]; low dose B. rhBMP-2 with poly [D,L-(lactide-co-glycolide)]; high dose	4 mo	2 mo	No differences (qualitative assessment)	High dose > low dose	Niti closed_coil spring; 100 g of force
Zhang et al. <sup>19</sup> (2011)	Animal study (dogs)	A. Alloplast: β-TCP with bMSCs B. Alloplast: β-TCP C. Autograft: iliac bone D. Control (no graft, no OTM)	8 wk	12 wk	Alloplast > alloplast with bMSCs = autograft (P < 0.05)	No significant RR in groups A, B and C	Sectional wire with niti-coil spring; 50 g of force
Seifi and Ghorraishian <sup>20</sup> (2012)	Animal study (dogs)	A. Alloplast: DFDBA B. Control (no graft)	Immediately	8 wk	Allograft > control (P < 0.05)	control > allograft (P < 0.05)	Niti closed_coil spring
Ahn et al. <sup>21</sup> (2014)	Animal study (dogs)	A. Xenograft: DBBM with demineralized bone matrix B. Control (no graft)	Immediately vs. 2 wk vs. 12 wk	6 wk	Xenograft_inmediate NR > control_2 wk > xenograft_12 wk > control_12 wk (P < 0.05)	NR	Niti closed_coil spring; 100 g of force
Seifi et al. <sup>22</sup> (2015)	Animal study (dogs)	A. Alloplast: nanocrystalline HA B. Control (no graft)	Immediately	8 wk	Control > alloplast (no statistical comparison)	No significant differences	Niti closed_coil spring; 150 g of force



Table 1. Continued

Author (yr)	Study design	Graft type	Time OTM after surgery	OTM duration	OTM difference	RR	Appliance; force applied
Kim et al. <sup>23</sup> (2015)	Animal study (dogs)	A. Xenograft: DBBM B. Xenograft: DBEM + LLLT C. Control (no graft)	Immediately vs. 2 wk	6 wk	Xenograft > control > xenograft_LLLT_2 wk	Xenograft_LLLT_2 wk > other groups	Sectional wire with niti closed_coilpring; 100 g of force
Tanimoto et al. <sup>24</sup> (2015)	Animal study (dogs)	A. Alloplast: (carbonated HA with bMSCs from iliac bone marrow) B. Alloplast: (carbonated HA alone)	6 mo	6 mo	No differences, but different rate in group B	Group B > group A	Elastic chain; 100 g of force
Machibya et al. <sup>25</sup> (2018)	Animal study (dogs)	A. Xenograft: DBBM with membrane B. Alloplast: $\beta$ -TCP with membrane C. Control (no graft) with membrane	4 wk vs. 8 wk	8 wk	Control > xenograft ( $P < 0.05$ )	NR	Niti closed_coilpring; 150 g of force
Jiang et al. <sup>26</sup> (2020)	Animal study (dogs)	A. Xenograft: DBBM with membrane B. Alloplast: BMP2-functionalized biomimetic CaP, with membrane C. Control (no graft)	1 wk	8 wk	No significant differences	Xenograft > alloplast > control ( $P < 0.05$ )	Sectional wire with niti closed_coilpring; 150 g of force
Abe et al. <sup>27</sup> (2023)	Animal study (dogs)	A. Xenograft: DBBM B. Alloplast: carbonated HA, granules	12 wk	10 mo	No significant differences	NR	Sectional wire with niti closed_coilpring; 100 g of force
de Ruiter et al. <sup>34</sup> (2011)	Animal study (goats)	A. Autograft: iliac bone B. Alloplast: $\beta$ -TCP	1 wk	6 mo	No significant differences	NR	Closed coils soldered to crowns; 50 cN of force
Klein et al. <sup>31</sup> (2019)	Animal study (mice)	A. Xenograft: DBBM B. Control (no graft)	4 wk	2 wk vs. 3 wk	Control > xenograft ( $P < 0.05$ )	NR	Niti closed_coilpring; 10 g of force
Klein et al. <sup>32</sup> (2020)	Animal study (mice)	A. Allograft: mice femurs and tibias B. Alloplast: $\beta$ -TCP C. Control (no graft)	4 wk	3 wk	Control > alloplast > allograft ( $P < 0.05$ )	NR	Niti closed_coilpring; 10 g of force
Oltamari et al. <sup>35</sup> (2007)	Animal study (mini-pigs)	A. Xenograft: DBB/bBMP/HA B. Control: blood clots	3 mo	4 mo	No significant differences	Control > xenograft ( $P < 0.05$ )	Sectional to implant and two niti closed_coilpring; 4.5 N of force

Table 1. Continued

Author (yr)	Study design	Graft type	Time OTM after surgery	OTM duration	OTM difference	RR	Appliance; force applied
Seif et al. <sup>36</sup> (2014)	Animal study (rabbits)	A. Allograft: DFDBA with LLLT B. Control: DFDBA without LLLT	Immediately	48 days	No significant differences	Control > LLLT group ( $P < 0.0001$ )	Niti closed_coil spring
Ru et al. <sup>28</sup> (2016)	Animal study (rats)	A. Alloplast: $\beta$ -TCP/HA B. Xenograft: DBBM C. Control: (no graft)	4 wk	4 wk	Control > alloplast = xenograft ( $P < 0.05$ )	Control > xenograft > alloplast ( $P < 0.05$ )	Niti closed_coil spring; 10 g of force
Möhlhenrich et al. <sup>29,30</sup> (2021, 2022)	Animal study (rats)	A. Autograft: iliac bone B. Xenograft: human bone C. Alloplast: $\beta$ -TCP/HA	4 wk	8 wk	No significant differences	No significant side effects	Niti closed_coil spring; 0.14 N of force

OTM, orthodontic tooth movement; RR, root resorption;  $\beta$ -TCP, beta-tricalcium phosphate; NR, not reported; niti, nickel-titanium; DBBM, deproteinized bovine bone mineral; rhBMP-2, recombinant human bone morphogenetic protein-2; bMSCs, bone marrow stromal cells; DFDBA, decalcified freeze-dried bone allograft; HA, hydroxyapatite; LLLT, low-level laser therapy; CaP, calcium phosphate; DBB/bBMP/HA, demineralized bovine cortical bone/bovine bone morphogenetic protein/hydroxyapatite.

ervation in the experimental site. Reduction of root resorption at the augmented site was significant compared to the unaltered healing site ( $P < 0.05$ ). The same authors carried out an experiments in rabbits<sup>36</sup> evaluating the effects of low-level laser therapy (LLLT) on OTM and root resorption after artificial socket preservation using the same allograft (DFDBA). The cycle was 10 days irritation, 14 days' rest, 10 days irritation, 14 days' rest, during the 48 days of the study. No significant differences were found in terms of OTM between the LLLT and the non-irradiated DFDBA grafted group. However, root resorption was significantly reduced in the LLLT group ( $0.18 \pm 0.07 \text{ mm}^2$ ) compared to the controls ( $1.61 \pm 0.43 \text{ mm}^2$ ) ( $P < 0.001$ ). The effect of laser irradiation on tooth movement is still a matter of controversy with heterogeneous effects reported using different laser irradiation periods, intensities and wavelengths. Further research is needed to evaluate the beneficial or deleterious effects of low-level laser on OTMs.

Another study<sup>32</sup> compared the dynamics of OTM into Allograft, Alloplast ( $\beta$ -TCP) regenerated bone and uneventfully healed bone (negative control group) in the mouse model. Both test groups showed a clear reduction of OTM following 3-week application of orthodontic force ( $648.3 \pm 31.6 \mu\text{m}$  in the allograft group;  $707.3 \pm 30.6 \mu\text{m}$  in the alloplast group;  $921.7 \pm 48.9 \mu\text{m}$  in the control group;  $P < 0.05$ ), although differences between the Allograft and Alloplast ( $\beta$ -TCP) groups were not statistically significant. these results demonstrating similar histological and radiographical healing of the grafted and control sites, while the regenerated bone demonstrated OTM impairment, was contradictory with results reported in dogs, with slight increase of OTM in DBDB grafted sites.<sup>20</sup> Graft-host compatibility and the degree of bone remodelling post-grafting can influence the rate of tooth movement through allografts and therefore, they may also influence the risk for root resorption.

### Xenografts

Tooth movement through xenografts can exhibit differences from natural bone mainly due differences in graft bio absorbability. Ten studies included in Table 1 have assessed OTM through Xenografts. Five included only a negative non-grafted control group (three performed in dogs,<sup>16,21,23</sup> one in mice,<sup>31</sup> and one in minipigs<sup>35</sup>); three included comparisons with Control and Alloplast groups (two in dogs<sup>25, 26</sup> and one in rats<sup>28</sup>); one in rats included a comparison with Autografts and Alloplasts groups;<sup>30</sup> and one included only a comparison with Alloplasts without control group.<sup>27</sup> Xenografts' integration, potential resorption rates, and the degree of bone remodelling could influence the speed of tooth movement. All studies used DBB except one,<sup>35</sup> that used a commercially available composite consisting of demin-

eralized bovine cortical bone matrix, inorganic porous bovine bone, collagen, and a bovine bone morphogenetic protein (bBMP) pool associated with microgranular synthetic hydroxyapatite (DBB/bBMP/HA); and one<sup>30</sup> that used human bone as xenograft in rats.

When OTM was applied to DBBM, two studies<sup>16,26</sup> showed no statistically significant differences compared to Control sites, or grafted with Autografts.<sup>30</sup> Also at DBB/bBMP/HA sites,<sup>35</sup> similar OTM was found compared with non-grafted controls. However, in three studies<sup>25,28,31</sup> slower OTM was reported in DBBM grafted sites compared to non-grafted controls, in spite of favourable radiological outcomes in DBBM sites (increased bone density and higher alveolar bone levels). One study found that immediate OTM movement was faster in DBB sites compared to control sites.<sup>21</sup> Another study including different timings and LLLT application, reported faster OTM in Xenograft grafted groups compared to non-grafted control sites,<sup>23</sup> while rates of OTM were significantly lower in the laser-irradiated groups compared to the nonirradiated groups. Low-level laser therapy significantly decreased the rate of OTM into the bone-grafted defects by accelerating defect healing and maturation, particularly when the start of postoperative OTM was delayed. The laser irradiated xenograft group LLLT exhibited less amount of OTM than the control group.

The comparisons between Xenografts and Alloplasts ( $\beta$ -TCP<sup>25</sup> or  $\beta$ -TCP/HA<sup>28,30</sup>), did not show significant differences in the rates of OTM. Also non-significant differences were reported when comparing DBBM and BMP2-functionalized biomimetic CaP,<sup>26</sup> nor between DBBM and granules of carbonated HA.<sup>27</sup>

In terms of root resorption, results are heterogeneous among the studies. Some did not report significant differences in root resorption,<sup>30</sup> or any differences between Xenograft and Control groups,<sup>16</sup> while others reported significantly higher root resorption in the Control compared with the Xenograft groups, both with DBB<sup>28</sup> or with DBB/bBMP/HA.<sup>35</sup> Conversely, other studies found higher incidence of root resorption in the Xenograft sites compared to Controls,<sup>26</sup> specially in LLLT- irradiated sites.<sup>23</sup>

When Xenografts were compared to Alloplasts, one study reported similar outcomes,<sup>30</sup> but two studies showed higher root resorption with xenografts than with alloplasts.<sup>26,28</sup>

Xenografts have shown a moderate risk of root resorption, probably due to differences in bone composition and potential immune reactions might impact the susceptibility of tooth roots to resorption during orthodontic movement.

### Alloplasts

OTM through alloplasts has shown similar rates or

slightly slower when compared to non-grafted sites. Six studies (Table 1), three in dogs,<sup>22,25,26</sup> one in rats,<sup>28</sup> one in mice,<sup>32</sup> and one in cats,<sup>33</sup> compared Alloplasts with Control non-grafted sites. Beta-tricalcium phosphate ceramics was the most commonly used alloplast, either alone<sup>25,32,33</sup> or in combination with HA.<sup>28</sup> OTM was faster in the control group than in  $\beta$ -TCP,<sup>28,32</sup> or showed similar results in both groups.<sup>25,33</sup> When OTM through BMP2-functionalized biomimetic CaP grafted sites was compared to control non-grafted sites, results were similar too.<sup>26</sup> Another study compared nanocrystalline HA with non-grafted controls and found that OTM was faster in control sites than grafted sites.<sup>22</sup> One study compared OTM through defects grafted with carbonated HA with bMSCs from iliac bone marrow of the implanted dogs, with defects grafted only with carbonated HA and found no significant differences in the total amount of movement, but the rate of tooth movement varied on the control side.<sup>24</sup>

Comparisons with other graft materials, autografts,<sup>19,30,34</sup> allografts,<sup>32</sup> and xenografts,<sup>25-28,30</sup> have been mentioned above.

In regards to root resorption, no differences between nanocrystalline HA<sup>22</sup> and control sites have been reported. Root resorption was higher in BMP2-functionalized biomimetic CaP when compared to control sites,<sup>26</sup> but lower than control sites when  $\beta$ -TCP/HA was used.<sup>28</sup> When carbonated HA with bMSCs was compared to carbonated HA alone, root resorption was found in this second group.<sup>24</sup> These heterogeneous results on the risk for root resorption may be related to the biomaterial composition and varying osteoconductive properties.

### Growth factors and biological factors

The use of growth factors and other biologicals may influence the bone remodelling process during orthodontic treatment, potentially affecting the rate and quality of bone turnover around teeth, hence potentially impacting the speed or direction of tooth movement.

Recombinant human bone morphogenetic protein-2 has been tested in two studies in dogs. One<sup>17</sup> included a Control group, where the defect was left empty, and an Autograft group. Although OTM was similar in the three groups, the incidence of root resorption was higher in the rhBMP-2 group.

The same authors compared high dose (40  $\mu$ g/100 mL) rhBMP-2 with a lower dose (10  $\mu$ g/100 mL).<sup>18</sup> reporting no effect on OTM, but with a lower incidence of root resorption in the low dose group. Also, the onset of bone remodeling occurred significantly earlier in low-dose rhBMP-2.

One study done in dogs,<sup>19</sup> compared three types of grafts: autograft of iliac crest,  $\beta$ -TCP alone, and in combination with bMSCs. Authors found that bMSCs



combined with  $\beta$ -TCP scaffold resulted in higher bone formation and mineralization than the  $\beta$ -TCP scaffold alone. Orthodontic tooth movement however, was faster in the  $\beta$ -TCP group, compared with both autograft and  $\beta$ -TCP plus bMSCs groups, probably due to the lower resistance due to lesser bone density in the  $\beta$ -TCP scaffold alone defects. Results indicated that the tissue-engineered complex with bMSCs/ $\beta$ -TCP dramatically promoted new bone formation and mineralization and achieved a favorable height of the repaired alveolar when compared with  $\beta$ -TCP alone, demonstrating severe resorption. The overall effect of the tissue-engineered bone was equivalent to autologous bone, allowing the adjacent teeth to move into the newly formed bone in the grafted region.

### **INFLUENCE OF DIFFERENT GRAFT MATERIALS ON ORTHODONTIC TOOTH MOVEMENT: CLINICAL STUDIES**

Different controlled clinical trials,<sup>7</sup> retrospective<sup>37-39</sup> and case-series<sup>40-42</sup> studies have evaluated the effect of combining periodontal and bone regenerative interventions and orthodontic therapy, reporting favorable and stable long-term results, with maintenance of attachment levels. One split-mouth RCT<sup>43</sup> found improvements in periodontal clinical and radiographic parameters following OTM and adjunctive use of low-level diode laser therapy after periodontal regenerative therapy for the management of intrabony defects in chronic periodontitis patients where defects were filled with a bioactive glass. Results from a parallel RCT<sup>44</sup> that compared the clinical efficacy of limited orthodontics combined with EMD/DFDBA in the treatment of 2- or 3-wall intrabony defects concluded that limited orthodontics provided an additional periodontal benefit to EMD/DFDBA in 2-wall defects compared to the group that did not receive orthodontic therapy.

These clinical studies together with data from observational studies have shown that current periodontal regenerative techniques are able to achieve significant periodontal attachment level gains in teeth with intrabony defect,<sup>45</sup> what may positively impact the ensuing orthodontic treatments by providing a more favourable environment for tooth movement and stability within the regenerated structures. Moreover, early OTM may not jeopardize the regenerative effect, but on the contrary, it may have the potential to improve the overall efficiency of the treatment due to augmented biological activity.<sup>46,47</sup>

### **TIMING OF OTM INITIATION AFTER REGENERATIVE SURGERY**

Time plays an important factor in the resorption process of the graft and the replacement by new bone. Therefore, the optimal interval between regenerative periodontal surgery and orthodontic therapy is a critical consideration influencing treatment outcomes. Initiating OTM too early may compromise the regeneration process by subjecting the newly formed tissues to excessive forces, leading to potential damage or disruption of the healing site. On the contrary, delaying the initiation of OTM could prevent the use of the full regenerative tissue potential, what may reduce the efficiency of the tooth movement, and might prolong the overall treatment duration without significant benefits.

A significant reduction of treatment time and better oral health related quality of life was reported recently in a multicenter RCT<sup>46</sup> that compared a time interval of 4 weeks versus 6 months in stage IV periodontitis patients that underwent regenerative surgery with Bio-Oss as grafting material, in combination with orthodontic therapy. Periodontal outcomes were also reported 12 and 24 months after surgery. At 12 months,<sup>48</sup> no statistically significant differences between groups could be observed for clinical attachment level (CAL) gain and probing pocket depth. However, at 24 months, CAL gain was significantly higher in the early treatment group. The results of this RCT suggest that long healing periods are not needed.

In another split-mouth controlled clinical study,<sup>7</sup> intrabony defects of periodontitis patients were treated with bioactive glass particles and collagen membrane. Each patient presented 3 defects, that received a) no OTM, b) immediate OTM, and c) OTM after 2 months. Results showed that OTM achieved significant improvement in periodontal clinical (pocket reduction and CAL) and radiographic parameters (increase in bone density and bone fill). When comparing the different groups, a statistically significant difference was found with immediate application of OTM.

The fact that the regenerative procedures may be enhanced during OTM, and that its effectiveness may vary depending on when the OTM is initiated, has also been proven in experimental studies. In a study on guinea-pigs,<sup>49</sup> evaluating the effectiveness of different times of initiating OTM on defects grafted with bioactive glass particles and collagen membranes, the immediate group revealed the greatest number of newly formed trabeculae and total surface area of newly formed bone than the other experimental groups.

As seen in Table 1, different animal experiments have used different timings of OTM initiation, ranging from immediate onset to 6 months<sup>24</sup> after surgery. An obser-

vation found in most of the studies is a trend in tooth movement reduction from onset of OTM to the end of the experiment, despite regular appliance activations, confirming that the tooth movement rate relies on the density of the alveolar bone.

Three studies<sup>21,23,25</sup> have compared the effect of different timings on the amount of OTM and presence of adverse effects, such as root resorption. All of them have included DBBM grafted defects compared to non-grafted control defects. In one study LLLT was applied combined with DBBM, and another study included a group treated with  $\beta$ -TCP.

Ahn et al.<sup>21</sup> compared DBBM grafted sites with non-grafted sites, applying the OTM either immediately after the surgery, or 2 weeks and 12 weeks after. Both the OTM rate and the mean appositional length of mineralized bone in the tension side of teeth were significantly increased when force was applied at 2 weeks in the control group and immediately in the experimental group ( $P < 0.001$ ). The 12-week groups, particularly the control non-grafted group, showed the slowest rate.

Machibya et al.<sup>25</sup> compared three groups of defects: DBBM,  $\beta$ -TCP, and non-grafted controls, where OTM was initiated 2 weeks and 4 weeks after surgery. The DBBM early and DBBM late subgroups reported the lowest amount of OTM compared with the other groups. The control group was inferior on bone density and bone height compared with the grafted groups (DBBM and  $\beta$ -TCP) but displayed the highest rate of OTM in the early group. The late OTM subgroup had favorable radiologic features and showed faster tooth movement than the early OTM in the  $\beta$ -TCP group.

Kim et al.<sup>23</sup> compared 2 timings of initiation of OTM (immediate and 2 weeks after surgery) in three groups of defects: DBBM alone, DBBM with LLLT, and non-grafted controls. The total amounts of OTM and new bone apposition rates were decreased by LLLT, with increased bone mineral density and trabecular maturation in the defects. Group LLLT\_2 weeks had the slowest movement with root resorption in relation to less woven bone in the hyper matured defect.

Based on these results, it can be concluded that shorter times are desirable in non-grafted defects, probably due to the presence of the Regional Acceleratory Phenomenon (RAP) that occurs right after surgical procedures, what expedites the bone remodelling process. Results favouring the late groups in the grafted groups could be explained by the time needed for the defect to begin integrating into the bone and reduce potential associated inflammation. However, when orthodontic force is applied shortly after graft implantation, the tooth moves through immature, less-mineralized bone. Consequently, the findings from these studies might not purely demonstrate the impact of regenerative mate-

rial on OTM itself. Conversely, delaying the application of force enables bone regeneration to progress, resulting in a slower tooth movement through mature, well-organized, and mineralized tissue.

It is important to mention that timing in animal studies cannot be directly extrapolated to timing in humans due to the differences among species in the duration of the biological processes. The ideal moment to start to apply orthodontic forces should consider a period for bone healing and regeneration, influenced by how quickly the material degrades and the metabolism of each species. Conversely, mechanical forces prompt both bone remodelling and graft degradation, indicating no necessity to wait for complete bony healing.

## MAGNITUDE OF FORCE OF OTM

The magnitude and direction of orthodontic forces applied during tooth movement through grafted bone significantly impact the risk of root resorption. Excessive force or inappropriate force vectors can elevate this risk. In human studies, controlled light and continuous forces are applied in most cases. However, in the experiments considered in this review, there is a high variability regarding the force magnitude and duration for tooth movement, what could explain the heterogeneity in the reported results.

## CLINICAL IMPLICATIONS

The findings underscore the significance of material selection in periodontal grafting for practitioners engaged in orthodontic treatments. Understanding the influence of graft materials on OTM is crucial in achieving optimal treatment outcomes. Clinicians must meticulously weigh the biological properties, limitations, and clinical implications of each graft material to tailor treatment strategies effectively. Patient-specific factors, such as the extent of bone loss, treatment goals, and individual preferences, should guide the selection process.

Each graft material's unique properties, biocompatibility, integration with surrounding tissues, and potential influence on bone remodelling affect the rate of tooth movement. Understanding these differences is crucial for clinicians in predicting treatment duration and optimizing orthodontic outcomes based on the chosen graft material. Further research continues to explore these nuances to refine treatment strategies in orthodontics and periodontics.

Understanding the potential risk of root resorption when moving teeth through grafted bone is crucial for treatment planning. Orthodontists must carefully balance the necessity of achieving tooth movement with the preservation of root structure to minimize the risk of

complications and ensure long-term dental health and stability.

## CONCLUSIONS

In conclusion, the influence of different materials used in periodontal grafting on OTM is multifaceted. Autografts demonstrate superior biological properties but are accompanied by limitations in donor availability and potential morbidity. Allografts and xenografts offer alternatives but present concerns regarding immunogenicity, integration, and potential resorption. Synthetic graft materials, while promising, necessitate further investigation for their role in supporting OTM. This review highlights the need for continued research and emphasizes the critical role of material selection in achieving successful outcomes in orthodontics and periodontal health.

## AUTHOR CONTRIBUTIONS

Conceptualization: CM, MS. Formal analysis: CM, MS. Investigation: CM. Methodology: CM. Writing—original draft: CM, MS. Writing—review & editing: CM, MS.

## CONFLICTS OF INTEREST

No potential conflict of interest relevant to this article was reported.

## FUNDING

None to declare.

## REFERENCES

- Kim Y. Study on the perception of orthodontic treatment according to age: a questionnaire survey. *Korean J Orthod* 2017;47:215-21. <https://doi.org/10.4041/kjod.2017.47.4.215>
- Herrera D, Sanz M, Kepschull M, Jepsen S, Sculean A, Berglundh T, et al. Treatment of stage IV periodontitis: the EFP S3 level clinical practice guideline. *J Clin Periodontol* 2022;49 Suppl 24:4-71. <https://doi.org/10.1111/jcpe.13639>
- Zasčiurinskienė E, Bulotaitė S, Bjerklin K, Lodienė G, Šidlauskas A, Zaborskis A. Knowledge, attitudes, and interest in orthodontic treatment: a cross-sectional study in adults with stage III-IV periodontitis and secondary malocclusions. *BMC Oral Health* 2023;23:853. <https://doi.org/10.1186/s12903-023-03605-8>
- Sanz M, Herrera D, Kepschull M, Chapple I, Jepsen S, Berglundh T, et al. Treatment of stage I-III periodontitis—the EFP S3 level clinical practice guideline. *J Clin Periodontol* 2020;47(Suppl 22):4-60. <https://doi.org/10.1111/jcpe.13290> Erratum in: *J Clin Periodontol* 2021;48:163. <https://doi.org/10.1111/jcpe.13403>
- Nibali L, Koidou VP, Nieri M, Barbato L, Pagliaro U, Cairo F. Regenerative surgery versus access flap for the treatment of intra-bony periodontal defects: a systematic review and meta-analysis. *J Clin Periodontol* 2020;47 Suppl 22:320-51. <https://doi.org/10.1111/jcpe.13237>
- Sculean A, Nikolidakis D, Nikou G, Ivanovic A, Chapple IL, Stavropoulos A. Biomaterials for promoting periodontal regeneration in human intrabony defects: a systematic review. *Periodontol* 2000 2015;68:182-216. <https://doi.org/10.1111/prd.12086>
- Attia MS, Shoreibah EA, Ibrahim SA, Nassar HA. Regenerative therapy of osseous defects combined with orthodontic tooth movement. *J Int Acad Periodontol* 2012;14:17-25. <https://pubmed.ncbi.nlm.nih.gov/22479985/>
- Alalola B, Asiri A, Binmoghaiseeb I, Baharoon W, Alrassi Y, Alanizy B, et al. Impact of bone-grafting materials on the rate of orthodontic tooth movement: a systematic review. *Cureus* 2023;15:e44535. <https://doi.org/10.7759/cureus.44535>
- Nibali L, Sultan D, Arena C, Pelekos G, Lin GH, Tonetti M. Periodontal infrabony defects: systematic review of healing by defect morphology following regenerative surgery. *J Clin Periodontol* 2021;48:100-13. <https://doi.org/10.1111/jcpe.13381>
- Stavropoulos A, Bertl K, Sculean A, Kantarci A. Regenerative periodontal therapy in intrabony defects and long-term tooth prognosis. *Dent Clin North Am* 2022;66:103-9. <https://doi.org/10.1016/j.cden.2021.09.002>
- Moqadam AS, Arash V, Mirzaie M, Fereydooni M, Haghani H, Rahmani A. Effect of alveolar ridge preservation with PDFDBA on orthodontic tooth movement rate, formation of gingival invagination and root resorption: a randomized, controlled pilot study. *Biomed Pharmacol J* 2016;9:3. <https://doi.org/10.13005/bpj/1072>
- Tehranchi A, Behnia H, Pourdaneh F, Behnia P, Pinto N, Younessian F. The effect of autologous leukocyte platelet rich fibrin on the rate of orthodontic tooth movement: a prospective randomized clinical trial. *Eur J Dent* 2018;12:350-7. [https://doi.org/10.4103/ejd.ejd\\_424\\_17](https://doi.org/10.4103/ejd.ejd_424_17)
- Reyes Pacheco AA, Collins JR, Contreras N, Lantigua A, Pithon MM, Tanaka OM. Distalization rate of maxillary canines in an alveolus filled with leukocyte-platelet-rich fibrin in adults: a randomized controlled clinical split-mouth trial. *Am J Orthod*

- Dentofacial Orthop 2020;158:182-91. <https://doi.org/10.1016/j.ajodo.2020.03.020>
14. Barhate UH, Duggal I, Mangaraj M, Sharan J, Duggal R, Jena AK. Effects of autologous leukocyte-platelet rich fibrin (L-PRF) on the rate of maxillary canine retraction and various biomarkers in gingival crevicular fluid (GCF): a split mouth randomized controlled trial. *Int Orthod* 2022;20:100681. <https://doi.org/10.1016/j.ortho.2022.100681>
  15. Hossain MZ, Kyomen S, Tanne K. Biologic responses of autogenous bone and beta-tricalcium phosphate ceramics transplanted into bone defects to orthodontic forces. *Cleft Palate Craniofac J* 1996;33:277-83. [https://doi.org/10.1597/1545-1569\\_1996\\_033\\_0277\\_broaba\\_2.3.co\\_2](https://doi.org/10.1597/1545-1569_1996_033_0277_broaba_2.3.co_2)
  16. Araújo MG, Carmagnola D, Berglundh T, Thilander B, Lindhe J. Orthodontic movement in bone defects augmented with Bio-Oss. An experimental study in dogs. *J Clin Periodontol* 2001;28:73-80. <https://pubmed.ncbi.nlm.nih.gov/11142670/>
  17. Kawamoto T, Motohashi N, Kitamura A, Baba Y, Takahashi K, Suzuki S, et al. A histological study on experimental tooth movement into bone induced by recombinant human bone morphogenetic protein-2 in beagle dogs. *Cleft Palate Craniofac J* 2002;39:439-48. [https://doi.org/10.1597/1545-1569\\_2002\\_039\\_0439\\_ahsoet\\_2.0.co\\_2](https://doi.org/10.1597/1545-1569_2002_039_0439_ahsoet_2.0.co_2)
  18. Kawamoto T, Motohashi N, Kitamura A, Baba Y, Suzuki S, Kuroda T. Experimental tooth movement into bone induced by recombinant human bone morphogenetic protein-2. *Cleft Palate Craniofac J* 2003;40:538-43. [https://doi.org/10.1597/1545-1569\\_2003\\_040\\_0538\\_etmibi\\_2.0.co\\_2](https://doi.org/10.1597/1545-1569_2003_040_0538_etmibi_2.0.co_2)
  19. Zhang D, Chu F, Yang Y, Xia L, Zeng D, Uludağ H, et al. Orthodontic tooth movement in alveolar cleft repaired with a tissue engineering bone: an experimental study in dogs. *Tissue Eng Part A* 2011;17:1313-25. <https://doi.org/10.1089/ten.TEA.2010.0490>
  20. Seifi M, Ghorraishian SA. Determination of orthodontic tooth movement and tissue reaction following demineralized freeze-dried bone allograft grafting intervention. *Dent Res J (Isfahan)* 2012;9:203-8. <https://pubmed.ncbi.nlm.nih.gov/22623939/>
  21. Ahn HW, Ohe JY, Lee SH, Park YG, Kim SJ. Timing of force application affects the rate of tooth movement into surgical alveolar defects with grafts in beagles. *Am J Orthod Dentofacial Orthop* 2014;145:486-95. <https://doi.org/10.1016/j.ajodo.2013.12.021>
  22. Seifi M, Arayesh A, Shamloo N, Hamedi R. Effect of nanocrystalline hydroxyapatite socket preservation on orthodontically induced inflammatory root resorption. *Cell J* 2015;16:514-27. <https://doi.org/10.22074/cellj.2015.496>
  23. Kim KA, Choi EK, Ohe JY, Ahn HW, Kim SJ. Effect of low-level laser therapy on orthodontic tooth movement into bone-grafted alveolar defects. *Am J Orthod Dentofacial Orthop* 2015;148:608-17. <https://doi.org/10.1016/j.ajodo.2015.04.034>
  24. Tanimoto K, Sumi K, Yoshioka M, Oki N, Tanne Y, Awada T, et al. Experimental tooth movement into new bone area regenerated by use of bone marrow-derived mesenchymal stem cells. *Cleft Palate Craniofac J* 2015;52:386-94. <https://doi.org/10.1597/12-232>
  25. Machibya FM, Zhuang Y, Guo W, You D, Lin S, Wu D, et al. Effects of bone regeneration materials and tooth movement timing on canine experimental orthodontic treatment. *Angle Orthod* 2018;88:171-8. <https://doi.org/10.2319/062017-407>
  26. Jiang S, Liu T, Wu G, Li W, Feng X, Pathak JL, et al. BMP2-functionalized biomimetic calcium phosphate graft promotes alveolar defect healing during orthodontic tooth movement in beagle dogs. *Front Bioeng Biotechnol* 2020;8:517. <https://doi.org/10.3389/fbioe.2020.00517>
  27. Abe T, Kunimatsu R, Tanimoto K. Comparison of orthodontic tooth movement of regenerated bone induced by carbonated hydroxyapatite or deproteinized bovine bone mineral in beagle dogs. *Materials (Basel)* 2023;17:112. <https://doi.org/10.3390/ma17010112>
  28. Ru N, Liu SS, Bai Y, Li S, Liu Y, Wei X. Bone Ceramic graft regenerates alveolar defects but slows orthodontic tooth movement with less root resorption. *Am J Orthod Dentofacial Orthop* 2016;149:523-32. <https://doi.org/10.1016/j.ajodo.2015.09.027>
  29. Möhlhenrich SC, Kniha K, Magnuska Z, Hermanns-Sachweh B, Gremse F, Hölzle F, et al. Evaluation of different grafting materials for alveolar cleft repair in the context of orthodontic tooth movement in rats. *Sci Rep* 2021;11:13586. <https://doi.org/10.1038/s41598-021-93033-x>
  30. Möhlhenrich SC, Kniha K, Magnuska Z, Chhatwani S, Hermanns-Sachweh B, Gremse F, et al. Development of root resorption during orthodontic tooth movement after cleft repair using different grafting materials in rats. *Clin Oral Investig* 2022;26:5809-21. <https://doi.org/10.1007/s00784-022-04537-3>
  31. Klein Y, Fleissig O, Stabholz A, Chaushu S, Polak D. Bone regeneration with bovine bone impairs orthodontic tooth movement despite proper osseous wound healing in a novel mouse model. *J Periodontol* 2019;90:189-99. <https://doi.org/10.1002/JPER.17-0550>
  32. Klein Y, Kunthawong N, Fleissig O, Casap N, Polak D, Chaushu S. The impact of alloplast and allograft on bone homeostasis: orthodontic tooth movement



- into regenerated bone. *J Periodontol* 2020;91:1067-75. <https://doi.org/10.1002/JPER.19-0145>
33. Sheats RD, Strauss RA, Rubenstein LK. Effect of a resorbable bone graft material on orthodontic tooth movement through surgical defects in the cat mandible. *J Oral Maxillofac Surg* 1991;49:1299-303; discussion 1304. [https://doi.org/10.1016/0278-2391\(91\)90307-8](https://doi.org/10.1016/0278-2391(91)90307-8)
  34. de Ruiter A, Meijer G, Dormaar T, Janssen N, van der Bilt A, Slootweg P, et al. TCP versus autologous bone for repair of alveolar clefts in a goat model. *Cleft Palate Craniofac J* 2011;48:654-62. <https://doi.org/10.1597/09-219>
  35. Ultramari PV, de Lima Navarro R, Henriques JF, Taga R, Cestari TM, Ceolin DS, et al. Orthodontic movement in bone defects filled with xenogenic graft: an experimental study in minipigs. *Am J Orthod Dentofacial Orthop* 2007;131:302.e10-7. <https://doi.org/10.1016/j.ajodo.2006.07.020>
  36. Seifi M, Atri F, Yazdani MM. Effects of low-level laser therapy on orthodontic tooth movement and root resorption after artificial socket preservation. *Dent Res J (Isfahan)* 2014;11:61-6. <https://pubmed.ncbi.nlm.nih.gov/24688562/>
  37. Tietmann C, Brösel F, Axelrad T, Jepsen K, Jepsen S. Regenerative periodontal surgery and orthodontic tooth movement in stage IV periodontitis: a retrospective practice-based cohort study. *J Clin Periodontol* 2021;48:668-78. <https://doi.org/10.1111/jcpe.13442>
  38. Tietmann C, Jepsen S, Heibrok H, Wenzel S, Jepsen K. Long-term stability of regenerative periodontal surgery and orthodontic tooth movement in stage IV periodontitis: 10-year data of a retrospective study. *J Periodontol* 2023;94:1176-86. <https://doi.org/10.1002/JPER.23-0081>
  39. Tu CC, Lo CY, Chang PC, Yin HJ. Orthodontic treatment of periodontally compromised teeth after periodontal regeneration: a retrospective study. *J Formos Med Assoc* 2022;121:2065-73. <https://doi.org/10.1016/j.jfma.2022.02.021>
  40. Ghezzi C, Vigano V, Francinetti P, Zanotti G, Masiero SA. Orthodontic treatment after induced periodontal regeneration in deep infrabony defects. *Clin Adv Periodontics* 2013;3:24-31. <https://doi.org/10.1902/cap.2012.110085>
  41. Ghezzi C, Masiero S, Silvestri M, Zanotti G, Rasperini G. Orthodontic treatment of periodontally involved teeth after tissue regeneration. *Int J Periodontics Restorative Dent* 2008;28:559-67. <https://pubmed.ncbi.nlm.nih.gov/19146051/>
  42. Cardaropoli D, Re S, Manuzzi W, Gaveglio L, Cardaropoli G. Bio-Oss collagen and orthodontic movement for the treatment of infrabony defects in the esthetic zone. *Int J Periodontics Restorative Dent* 2006;26:553-9. <https://pubmed.ncbi.nlm.nih.gov/17243328/>
  43. Attia MS, Hazzaa HH, Al-Aziz FA, Elewa GM. Evaluation of adjunctive use of low-level diode laser biostimulation with combined orthodontic regenerative therapy. *J Int Acad Periodontol* 2019;21:63-73. <https://pubmed.ncbi.nlm.nih.gov/31522153/>
  44. Ogiyama S, Wang HL. Periodontal regeneration with or without limited orthodontics for the treatment of 2- or 3-wall infrabony defects. *J Periodontol* 2010;81:1734-42. <https://doi.org/10.1902/jop.2010.100127>
  45. Zampara E, Alshammari M, De Bortoli J, Mullings O, Gkisakis IG, Benalcázar Jalkh EB, et al. A histologic and histomorphometric evaluation of an allograft, xenograft, and alloplast graft for alveolar ridge preservation in humans: a randomized controlled clinical trial. *J Oral Implantol* 2022;48:541-9. <https://doi.org/10.1563/aaid-joi-D-21-00012>
  46. Jepsen K, Tietmann C, Martin C, Kutschera E, Jäger A, Wüllenweber P, et al. Synergy of regenerative periodontal surgery and orthodontics improves quality of life of patients with stage iv periodontitis: 24-month outcomes of a multicenter RCT. *Bioengineering (Basel)* 2023;10:695. <https://doi.org/10.3390/bioengineering10060695>
  47. Vardimon AD, Nemcovsky CE, Dre E. Orthodontic tooth movement enhances bone healing of surgical bony defects in rats. *J Periodontol* 2001;72:858-64. <https://doi.org/10.1902/jop.2001.72.7.858>
  48. Jepsen K, Tietmann C, Kutschera E, Wüllenweber P, Jäger A, Cardaropoli D, et al. The effect of timing of orthodontic therapy on the outcomes of regenerative periodontal surgery in patients with stage IV periodontitis: a multicenter randomized trial. *J Clin Periodontol* 2021;48:1282-92. <https://doi.org/10.1111/jcpe.13528>
  49. Attia MS, Shoreibah EA, Ibrahim SA, Nassar HA. Histological evaluation of osseous defects combined with orthodontic tooth movement. *J Int Acad Periodontol* 2012;14:7-16. <https://pubmed.ncbi.nlm.nih.gov/22479984/>