

What can a dentist learn from an astrophysicist? A photographic evaluation of the long-term impact of amyotrophic lateral sclerosis on the orofacial sphere, using the example of Stephen Hawking: A historical case report

Vincent Vaudroz¹  | Stavros Kiliaridis^{1,2} | Gregory S. Antonarakis¹

¹ Division of Orthodontics, University Clinics of Dental Medicine, University of Geneva, 1 rue Michel-Servet, Geneva 1206, Switzerland

² Department of Orthodontics and Dentofacial Orthopedics, University of Bern, Freiburgstrasse 7, Bern CH-3010, Switzerland

Correspondence

Vincent Vaudroz, Division of Orthodontics, University Clinics of Dental Medicine, University of Geneva, 1 rue Michel-Servet, 1206 Geneva, Switzerland
Email: vincent.vaudroz@unige.ch

Funding information

The Division of Orthodontics of the University Clinics of Dental Medicine of the University of Geneva funded the current project.

[Correction added on October 30, 2021, after first online publication: Affiliation 1, correspondence section, and funding information have been updated].

Abstract

Aims: The present historical case report aims to characterize the long-term orofacial repercussions of amyotrophic lateral sclerosis (ALS), a rare neurodegenerative disease with poor prognosis and relatively short life expectancy following initial diagnosis.

Methods: Here we focus on the long-term orofacial evolution seen in the example of Stephen Hawking, one of the greatest personalities in the scientific world, using publicly-available photographic documentation. The fact that Stephen Hawking lived several decades following his diagnosis of ALS presents one with a unique opportunity to characterize and follow-up the evolution of the ALS on the orofacial sphere. Through this article, we want to show him and his family, and all those living with this disease, our deepest respect, without intending in any way to intrude or misuse the privacy of the late universally-respected astrophysicist.

Results: Photographic documentation analyzed longitudinally shows changes towards the development of a Class III malocclusion, lower incisor protrusion, and a concave profile. Moreover, tooth wear has occurred, accompanied by posterior tooth loss and aberrant tongue and lip posture.

Conclusion: The causes of such changes remain speculative but could be due to changes in the soft tissue equilibrium, changes in head and tongue posture, loss of oral function, respiratory needs, and a general deterioration of dental health. Our sincere thanks to the Hawking family who took the time to read the article and approve its publication for scientific and educational purposes. We are also deeply grateful to them for providing us with some photographs from their family collection.

KEYWORDS

amyotrophic lateral sclerosis, extraoral photography, malocclusion, oral health

This is an open access article under the terms of the [Creative Commons Attribution-NonCommercial-NoDerivs](https://creativecommons.org/licenses/by-nc-nd/4.0/) License, which permits use and distribution in any medium, provided the original work is properly cited, the use is non-commercial and no modifications or adaptations are made.

© 2021 The Authors. *Special Care in Dentistry* published by Special Care Dentistry Association and Wiley Periodicals LLC

1 | INTRODUCTION

Amyotrophic lateral sclerosis (ALS) is a degenerative and progressive disease of the lower and upper motor neurons making it one of the most devastating neurodegenerative diseases. It affects motor neurons in the primary motor cortex, cortico-spinal tract, brainstem and spinal cord resulting in loss of mobility followed by muscle atrophy.^{6,13,24} The disease results in a selective loss of function of lower or upper motor neurons and is classified into two categories: the spinal-onset form, which is the most common; and the bulbar-onset form. The bulbar form has the least favorable prognosis due to problems including dysphagia, weight loss, and respiratory complications.²¹

The annual incidence of ALS is approximately 1–2.6 cases per 100,000 people,^{21,23} and the prevalence approaches 6/100,000.^{17,23} This rare disease commonly manifests around 58–60 years of age.^{7,23} People with this disease die most frequently from respiratory failure, and this occurs within 30–36 months after the initial diagnosis for 50% of patients. Of those who exceed this threshold, most patients generally die within 5–10 years post-diagnosis.^{5,6,17}

1.1 | Amyotrophic lateral sclerosis and the orofacial sphere

Dysphagia is one of the most common symptoms associated with this condition.¹⁸ It results in weight loss, made worse by chewing and psychological disorders, such as depression. The decrease in muscle strength also has repercussions on the diet, with patients being led to favor soft or crushed foods.³ In addition to the risk of aspiration, dysphagia causes food debris to persist in the mouth, which can promote the development of caries and periodontal disease.¹⁹ Dysphagia is usually preceded by dysarthria, a speech disorder associated with alterations in the motor pathways responsible for speech production.²³ There is hoarseness of the voice as well as problems with articulation partly due to the increased rigidity of the tongue.¹⁸

Tongue abnormalities are estimated to occur in about 60% of patients, while the presence of a coating on the tongue occurs in around 50% resulting in halitosis and increased risk of pneumonia.^{1,18} Tongue atrophy, weakness, as well as fasciculations of the tongue are frequently found due to the involvement of the hypoglossal neurons.¹⁵ The tongue hollows out causing grooves and bumps on its surface leading to difficulties in maintaining sufficient oral hygiene.³ A Japanese study reports that macroglossia is diagnosed in approximately 34% of patients undergoing tracheostomy with invasive ventilation (TIV) and being tube-fed. The affected patients had a significantly younger

age of onset, a longer total disease duration, a longer duration of TIV use, and a higher BMI than patients without macroglossia.¹⁵ This enlargement sometimes causes the tongue to protrude out of the oral cavity. An associated trismus can also be found in these patients.¹⁵

With regard to trismus, negative correlations between maximal mouth opening and the duration of the disease, as well as between maximal mouth opening and the duration of invasive respiratory support have been demonstrated.¹⁸ The maximum mouth opening is reduced to an average of 20 mm.²⁰ Difficulties with protrusive and lateral mandibular movements are also often present,³ and maximal bite force tends to decrease over time.²¹ Patients with ALS are however not prone to clenching or grinding their teeth,²¹ although mucosal injuries can occur.

Sialorrhea can also occur, and this is seen predominantly in patients with the bulbar form of ALS.²¹ This is seen as a consequence of a decrease in the strength of the tongue and perioral muscles, in addition to the reduction in swallowing frequency resulting in an accumulation of saliva in the oral cavity.^{3,4} Risks of sialorrhea include cheilitis, speech problems, sleep disturbances, coughing, and an increased risk of aspiration.¹⁶ Conversely, some patients can present with xerostomia caused by polypharmacy and/or by mouth breathing. Xerostomia can promote the development of caries,¹¹ induce nutritional problems by complicating the formation of a quality bolus and swallowing, and cause speech problems.³

1.2 | Amyotrophic lateral sclerosis and the potential development of malocclusions

Although no specific studies have been carried out looking at the development of malocclusions in individuals with ALS, one can use existing data to speculate about the potential changes.

Dental and orthodontic management of patients with ALS is challenging, and tooth extraction is usually the treatment of choice once problems arise, especially given the short life expectancy following diagnosis. ALS potentiates the development of periodontal pathologies,¹⁹ and active periodontitis can also lead to dental displacement and flaring and accelerate tooth loss. With the loss of teeth, dental displacements are likely to occur resulting in malocclusions, although once again the short life-expectancy does not allow major changes to become apparent. The main displacements following loss of molar antagonists are tipping, rotation and extrusions.¹²

Several symptoms or consequences of ALS can lead to an imbalance in the orofacial sphere. These different phenomena are found in other diseases and can in




FIGURE 1 Extraoral evolution of the face and profile of Stephen Hawking. From left to right and top to bottom: 1979 (37 years), 2008 (66 years), 2015 (73 years) 1985 (43 years), 2001 (59 years), and 2017 (75 years). The eyes and the base of the nose in each photograph have been aligned and the magnification of the photographs standardized within reasonable limits. The source of each corresponding photograph can be found in the appendix

particular be the cause of malocclusions. The examples that follow have significant consequences if they develop during growth. However, we support the hypothesis that these repercussions could be found in advanced ALS, although ALS manifests itself in adulthood.

For example, the main malocclusions found in people with Duchenne muscular dystrophy are posterior crossbites as well as anterior or lateral openbites.² Patients with cerebral palsy, where the position of the head at rest is affected, can also present with malocclusions. Patients with a hyperextended head position can exhibit more frequent changes such as a Class II malocclusion and a decrease in the overbite and an increase in overjet.¹⁴

In the presence of macroglossia, a plausible consequence of ALS, the balance dictated by the tongue, the perioral musculature of the lips and cheeks is disturbed. This phenomenon could be accentuated by atrophy of the facial muscles. This imbalance can result in transverse problems such as the appearance of posterior crossbites, interdental spacing, proclination of the lower incisors or even the creation of lateral openbites due to the lateral forces exerted on the lingual surfaces of the mandibular posterior teeth.²

Mouth breathing is often seen in patients with ALS. The patient lowers the mandible and tongue and tilts the head back to clear the upper airways. Maintaining these postural

changes long-term during growth can lead to an increase in facial height as a consequence of the overeruption of posterior teeth causing posterior rotation of the mandible, potentially resulting in openbite and increased overjet. An anterior position of the tongue at rest can also be responsible for the creation of an anterior openbite. The increase in pressure resulting from the stretching of the cheeks may also cause a decrease in the width of the maxillary arch.²⁵

2 | CASE REPORT AND DISCUSSION

The life of the late world-renowned astrophysicist, Stephen Hawking, presents one with a unique opportunity to characterize and follow-up the evolution of the ALS on the orofacial sphere. Although the average life expectancy following the diagnosis of ALS is on average three to four years,²³ Stephen Hawking lived with the disease for more than fifty years, and thus any effect of the disease on the orofacial sphere would have had time to manifest itself. The present historical case report aims to characterize the different long-term repercussions of ALS on the orofacial sphere using publicly-available photographic documentation of Stephen Hawking. We perform the present analysis with the assumption that all photographic material is




FIGURE 2 Dental evolution of Stephen Hawking, as witnessed through extraoral photographs, from his twenties to his late forties. From left to right and top to bottom: 1965 (23 years), 1971 (29 years), 1975 (33 years), 1979 (37 years), 1986 (44 years), and 1989 (47 years). The source of each corresponding photograph can be found in the appendix

authentic and has not succumbed to alterations using photographic manipulation software. All photographs used in the present case report have been identified on the internet and are used as is, without alterations, with the exception of photograph cropping and rotation. Only dated photographs are used and presented here, so as to be able to evaluate them chronologically.

2.1 | Extraoral evolution of the face and profile (Figure 1)

All of the photographs seen in Figure 1 are under the assumption that Stephen Hawking is at rest, probably with light interocclusal contacts, corresponding to a situation in the most stable position of the mandible.⁸ By analyzing

these photographs, one can see a gradual decrease in the height of the lower third of the face, with a corresponding loss of the vertical dimension with time. The establishment of a profile that becomes progressively more concave with more apparent mandibular protrusion is also observed, leading to greater exposure of the mandibular and less exposure of the maxillary teeth.

These repercussions observed are most probably the consequence of the loss of posterior teeth over the years causing an anterior mandibular rotation and a consequent vertical closure. More forward projection of the chin and loss of vertical dimension is aggravated, initially by the loss of the maxillary posterior teeth followed by the loss of the maxillary anterior teeth at the end of his life, resulting in more mandibular anterior rotation. This rotation, also seen in the elderly, is probably accelerated and accentuated by

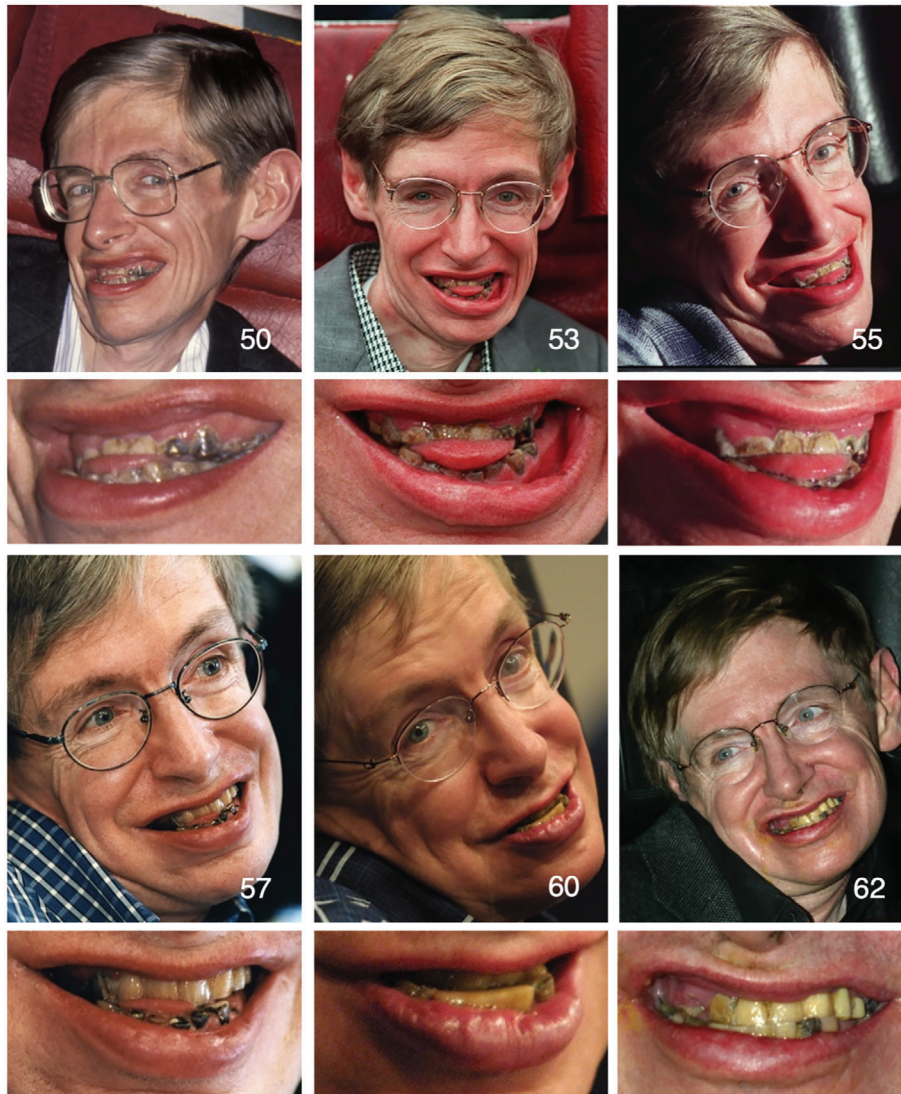

FIGURE 3 Dental evolution of Stephen Hawking, as witnessed through extraoral photographs, from his early fifties to his early sixties. From left to right and top to bottom: 1992 (50 years), 1995 (53 years), 1997 (55 years), 1999 (57 years), 2002 (60 years), and 2004 (62 years). The source of each corresponding photograph can be found in the appendix

the weakness of the facial musculature caused by muscle atrophy. The profile of his lower lip and the exposure of the mandibular incisors around the age of 73 years suggests that these teeth have proclined.

2.2 | Intraoral dental evolution (Figures 2 and 4)

The first picture (Figure 2), taken at the age of 23, two years after the diagnosis of ALS, most likely an unusual form of spinal-onset in its initial presentation, is used as the baseline picture, where it can be assumed that his intraoral situation had not yet been significantly affected by the disease. Gingival health seems to be maintained and the maxillary

anterior teeth are relatively well aligned within the arch. There is complete exposure of the upper central incisors, accompanied by a slight gummy smile. Overjet and overbite appear to be within the normal range.

From the age of 29 onwards, soon after the prescription of a wheelchair for mobility,¹⁰ we can notice the presence of gingivitis which becomes more severe over time. In the third image (Figure 2), we can see the presence of dental staining which may testify difficulties in maintaining sufficient oral hygiene. In his early forties, Stephen Hawking had to have a tracheostomy which was accompanied by the loss of the ability to speak.¹⁰ This event probably had a significant impact on his dental maintenance.

The difficulty in maintaining good oral hygiene quickly results in the onset of caries, possibly accompanied by




FIGURE 4 Dental evolution of Stephen Hawking, as witnessed through extraoral photographs, from his mid-sixties to his mid-seventies. From left to right and top to bottom: 2006 (64 years), 2008 (66 years), 2011 (69 years), 2013 (71 years), 2015 (73 years), and 2017 (75 years). The source of each corresponding photograph can be found in the appendix

periodontal problems. The presence of caries is also perhaps evident since the age of 30, especially on teeth number 22 and 23 which were likely restored several times throughout his life. At the age of 57 years, the presence of maxillary anterior restorations is evident, probably using fixed prostheses. The use of a removable prosthesis would probably not be recommended due to the aspiration risk. The tooth number 13 seems to have been lost at the age of 62 years, suggesting also the loss of additional posterior teeth in the first quadrant.

Moving on to his seventies, it can be assumed that unfortunately only the mandibular anterior restorations remained intact. Bridgework or perhaps implants may have been undertaken towards the end of his life as at the age of 75 there seem to be more teeth than a few

years earlier. These treatments may have primarily had an aesthetic purpose since there was a loss of oral function.

Caries and periodontal problems do not seem to be the only factors responsible for all of his restorations. Effectively from the age of 29 a decrease in the clinical crown height of the maxillary incisors is seen. The incisal edges and the embrasures seem reduced compared to the previous image, suggesting loss of tooth substance. This loss is progressive and appears to be due to attrition. Although erosion cannot be ruled out, we did not find any evidence linking ALS with gastroesophageal reflux disease or bruxism.

Moving on to his early fifties (Figure 3), the maxillary anterior teeth show an inverted incisal edge curvature due probably to progressive loss of substance, as well as to

the effects of the protruding tongue witnessed in these photographs. Tongue protrusion to clear the upper airway combined with a buccal acidic environment, are likely to be at the origin of this phenomenon.²²

The disturbance of the muscular balance of the orofacial sphere accompanied by the loss of several teeth can be responsible for dental displacement. Around the age of 30, mandibular anterior crowding seems to have occurred, with the proclination of one of the lower incisors. The crowding worsens with time and overjet also seems to decrease. This may be related to mandibular anterior rotation, which was evidenced on the extraoral photographs, and perhaps related to the loss of the posterior dentition and changes in muscular balance and the position of the tongue.

During his mid to late sixties, the apparent loss of the maxillary anterior teeth is observed. This loss of maxillary anterior and posterior teeth results in the increased mandibular rotation, loss of the vertical dimension, and the upper lip trap which is habitually seen behind the mandibular incisors. Proclination of the mandibular anterior teeth is also visible, perhaps due to this lip trap as well as tongue posture.

3 | CONCLUSION

The present historical case report supports the idea that ALS may be responsible for the long-term development of malocclusions. Many factors seem to have come into play, including tooth loss, loss of oral function, muscular imbalance, tongue posturing, changes in head posture and respiratory requirements. It remains to be determined with certainty which factors are more important in the development of these malocclusions. Unlike other degenerative diseases, such as Duchenne muscular dystrophy, ALS usually develops in adulthood. Therefore, with active growth already having been completed, there is less potential for the negative consequences of the disease in the development of orthodontic problems.² Finally, compromised oral health can have serious consequences for the well-being of patients already severely affected by the primary symptoms of the disease. It seems understandable that for the patients and their caregivers, oral hygiene may not be a priority. However, we advocate that it is essential to maintain a healthy oral situation in order to preserve an optimal quality of life.

ACKNOWLEDGMENTS

Through this article, the authors wish to show the late Stephen Hawking and his family, as well as all those living with this disease, our deepest respect, without intending in any way to intrude or misuse the privacy of the late

universally-respected astrophysicist. The authors sincerely thank the Hawking family who took the time to read the present article and approve its publication for scientific and educational purposes. We are also deeply grateful to them for providing us with some photographs from their private family collection.


Open access funding provided by the University of Geneva.

[Correction added on October 30, 2021, after first online publication: This section has been updated]

CONFLICT OF INTEREST

There are no conflicts of interest reported.

ORCID

Vincent Vaudroz  <https://orcid.org/0000-0003-0230-0026>

REFERENCES

1. Abe S, Ishihara K, Adachi M, Okuda K. Tongue-coating as risk indicator for aspiration pneumonia in edentate elderly. *Arch Gerontol Geriatr*. 2008;47(2):267–275. <https://doi.org/10.1016/j.archger.2007.08.005>
2. Antonarakis GS, Morel C, Kiliaridis S. Management of the dentoalveolar effects of tongue hypertrophy in patients with Duchenne muscular dystrophy: a pilot study. *Neuromuscul Disord*. 2020;30(2):105–110. <https://doi.org/10.1016/j.nmd.2019.11.009>
3. Bergendal B, McAllister A. Orofacial function and monitoring of oral care in amyotrophic lateral sclerosis. *Acta Odontol Scand*. 2017;75(3):179–185. <https://doi.org/10.1080/00016357.2016.1276212>
4. Cousins L. Motor neurone disease for dental professionals. MND Association 2017. 2017. Registered Charity No. 294354. 36. <https://dbsy278t81889.cloudfront.net/app/uploads/2012/04/19134958/MND-dentist-guide.pdf>
5. Ellison D, Love S. *NEUROPATHOLOGY A Reference Text of CNS Pathology*, 3rd ed. Maryland Heights, Missouri (United States): Edition Mosby Elsevier; 2013:879.
6. Kasper D. *Harrison's Principles of Internal Medicine*, 19th ed. New York City (United States): McGraw-Hill Professional, "McGraw-Hill Professional"; 2015:3000.
7. Dougall A, Fiske J. Access to special care dentistry, part 1. *Br Dent J*. 2008;204(11):605–616. <https://doi.org/10.1038/sj.bdj.2008.457>
8. Tilotta F, Lautrou A, Lévy G. *Anatomie Dentaire*, Paris (France): Elsevier Masson; Hors collection, 2018: 303.
9. Govoni V, Cesnik E, Casetta I, Tugnoli V, Tola MR, Granieri E. Temporal trend of amyotrophic lateral sclerosis incidence in southern Europe: a population study in the health district of Ferrara, Italy. *J Neurol*. 2012;259(8):1623–1631. <https://doi.org/10.1007/s00415-011-6390-5>
10. Hawking JW. Une merveilleuse histoire du temps: ma vie avec Stephen Hawking, Bernay (France), Edition Terra Nova (City Edition), "TERRA NOVA", 2015:448.

11. Jansma J, Vissink A, Jongebloed WL, s-Gravenmade EJ. Xerostomia-related dental caries. *Ned Tijdschr Tandheelkd.* 1992;99(6):225–32.
12. Kiliaridis S, Lyka I, Friede H, Carlsson GE, Ahlqwist M. Vertical Position, Rotation, and Tipping of Molars Without Antagonists. 7. 2000
13. Bear MF, Connors BW, Paradiso MA. *NEUROSCIENCE à la découverte du cerveau*, 3rd ed. Rueil-Malmaison (France): Edition Pradel; 2013:881.
14. Martinez-Mihi V, Silvestre F, Orellana Lm, Silvestre-Rangil J. Resting position of the head and malocclusion in a group of patients with cerebral palsy. *J Clin Exp Dent.* 2014:e1–e6. <https://doi.org/10.4317/jced.51129>
15. Matsuda C, Shimizu T, Nakayama Y, et al. Macroglossia in advanced amyotrophic lateral sclerosis: Macroglossia in ALS. *Muscle Nerve.* 2016;54(3):386–390. <https://doi.org/10.1002/mus.25058>
16. McGeachan AJ, Hobson EV, Al-Chalabi A, et al. A multicentre evaluation of oropharyngeal secretion management practices in amyotrophic lateral sclerosis. *Amyotroph Lateral Scler Front Degenerate.* 2017;18(1-2):1–9. <https://doi.org/10.1080/21678421.2016.1221433>
17. Mitchell JD & Borasio GD Amyotrophic lateral sclerosis. 2007;369:11.
18. Nakayama R, Nishiyama A, Matsuda C, Nakayama Y, Hakuta C, Shimada M. Oral health status of hospitalized amyotrophic lateral sclerosis patients: a single-centre observational study. *Acta Odontol Scand.* 2018;76(4):294–298. <https://doi.org/10.1080/00016357.2017.1420228>
19. Ortega O, Parra C, Zarcero S, Nart J, Sakwinska O, Clavé P. Oral health in older patients with oropharyngeal dysphagia. *Age Ageing.* 2014;43(1):132–137. <https://doi.org/10.1093/ageing/af164>
20. Pang KM, Park JW. Masticatory muscle pain and progressive mouth opening limitation caused by amyotrophic lateral sclerosis: a case report. *J Oral Facial Pain Headache.* 2015;29(1):91–96. <https://doi.org/10.11607/ofph.1340>
21. Riera-Punet N, Martinez-Gomis J, Paipa A, Povedano M, Peraire M. Alterations in the masticatory system in patients with amyotrophic lateral sclerosis. *J Oral Facial Pain Headache.* 2018;32(1):84–90. <https://doi.org/10.11607/ofph.1882>
22. Seong J, Claydon N, Macdonald E, Garner S, Newcombe RG, West N. A randomised clinical trial to determine the abrasive effect of the tongue on human enamel loss with and without a prior erosive challenge. *J Dent.* 2017;58:48–53. <https://doi.org/10.1016/j.jdent.2017.01.011>
23. Talbott EO, Malek AM, Lacomis D. The Epidemiology of Amyotrophic Lateral Sclerosis. *Handbook of Clinical Neurology*, 138. Elsevier; 2016:225–238. <https://doi.org/10.1016/B978-0-12-802973-2.00013-6>
24. Valente SM, Karp JR. Life with lou gehrig's disease: managing ALS symptoms. *Nur Practitioner: Am J Prim Healthcare.* 2007;32(12):26–33. <https://doi.org/10.1097/01.NPR.0000300824.66840.5d>
25. Proffit WR, Fields HW Jr, Larson B, Sarver DM. *Contemporary Orthodontics*, 6th ed. Missouri (United States): Edition Mosby Elsevier (Health Sciences Division); 2018: 744.

How to cite this article: Vaudroz V, Kiliaridis S, Antonarakis G. What can a dentist learn from an astrophysicist? A photographic evaluation of the long-term impact of amyotrophic lateral sclerosis on the orofacial sphere, using the example of Stephen Hawking: A historical case report. *Spec Care Dentist.* 2021;1-9. <https://doi.org/10.1111/scd.12665>

APPENDIX A

Origin of photographs

- a. British scientist Stephen Hawking attends the 2008 Cambridge... (n.d.). Getty Images. Retrieved September 16, 2021, from <https://www.gettyimages.ch/detail/nachrichtenfoto/british-scientist-stephen-hawking-attends-the-2008-nachrichtenfoto/82732163>
- b. British theoretical physicist Stephen Hawking receives an interview... (n.d.). Getty Images. Retrieved September 16, 2021, from <https://www.gettyimages.ch/detail/nachrichtenfoto/british-theoretical-physicist-stephen-hawking-receives-nachrichtenfoto/932559054>
- c. British theoretical physicist Stephen Hawking with student Chris... (n.d.). Getty Images. Retrieved September 16, 2021, from <https://www.gettyimages.ch/detail/nachrichtenfoto/british-theoretical-physicist-stephen-hawking-with-nachrichtenfoto/88232493>
- d. Cast member actress Jane Fonda kisses Physicist Stephen Hawking... Nachrichtenfoto—Getty Images. (n.d.). Retrieved September 16, 2021, from <https://www.gettyimages.ch/detail/nachrichtenfoto/cast-member-actress-jane-fonda-kisses-physicist-nachrichtenfoto/108727381>
- e. Cosmologist Stephen Hawking on October 10, 1979 in Princeton, New... (n.d.). Getty Images. Retrieved September 16, 2021, from <https://www.gettyimages.ch/detail/nachrichtenfoto/cosmologist-stephen-hawking-on-october-10-1979-in-nachrichtenfoto/476665113>
- f. Cosmologist Stephen Hawking visits the Temple of Heaven on June 18 in... (n.d.). Getty Images. Retrieved September 16, 2021, from <https://www.gettyimages.ch/detail/nachrichtenfoto/cosmologist-stephen-hawking-visits-the-temple-of-nachrichtenfoto/71236660>
- g. Dr. Stephen Hawking at the Empire, Leicester Square in London, United... News Photo—Getty

- Images. (n.d.). Retrieved September 16, 2021, from <https://www.gettyimages.co.uk/detail/news-photo/dr-stephen-hawking-at-the-empire-leicester-square-in-london-news-photo/74712753>
- h. PA NEWS PHOTO 15/9/95 PROFESSOR SCIENTIST STEPHEN HAWKING WHO SUFFERS... (n.d.). Getty Images. Retrieved September 16, 2021, from <https://www.gettyimages.ch/detail/nachrichtenfoto/pa-news-photo-15-9-95-professor-scientist-stephen-nachrichtenfoto/829996854>
- i. Physiker, Mathematiker, Grossbritannien- Porträt, lächeln Nachrichtenfoto—Getty Images. (n.d.). Retrieved September 16, 2021, from <https://www.gettyimages.ch/detail/nachrichtenfoto/physiker-mathematiker-grossbritannien-portr%C3%A4t-l%C3%A4cheln-nachrichtenfoto/541800387?adppopup=true>
- j. Professor Stephen Hawking addressing The Cambridge Union on November... Nachrichtenfoto—Getty Images. (n.d.-a). Retrieved September 16, 2021, from <https://www.gettyimages.ch/detail/nachrichtenfoto/professor-stephen-hawking-addressing-the-cambridge-nachrichtenfoto/877190400>
- k. Professor Stephen Hawking addressing The Cambridge Union on November... Nachrichtenfoto—Getty Images. (n.d.-b). Retrieved September 16, 2021, from <https://www.gettyimages.ch/detail/nachrichtenfoto/professor-stephen-hawking-addressing-the-cambridge-nachrichtenfoto/877190344?adppopup=true>
- l. Professor Stephen Hawking, Cambridge June 1975 . (n.d.). Getty Images. Retrieved 16 September 2021, from <https://www.gettyimages.ch/detail/nachrichtenfoto/professor-stephen-hawking-cambridge-june-1975-nachrichtenfoto/993648014>
- m. SF.Hawking.1.bv.25/PASADENA Theoretical physicist Stephen Hawking... Nachrichtenfoto—Getty Images. (n.d.). Retrieved September 16, 2021, from <https://www.gettyimages.ch/detail/nachrichtenfoto/hawking-1-bv-25-pasadena-theoretical-physicist-nachrichtenfoto/567401287?adppopup=true>
- n. Stephen Hawking at his wedding | Stephen hawking young, Stephen hawking, Steven hawking. (n.d.). Pinterest. Retrieved September 16, 2021, from <https://www.pinterest.com/pin/319403798581125582/>
- o. Stephen Hawking attends the EE British Academy Film Awards at The... Nachrichtenfoto—Getty Images. (n.d.). Retrieved September 16, 2021, from <https://www.gettyimages.ch/detail/nachrichtenfoto/stephen-hawking-attends-the-ee-british-academy-film-nachrichtenfoto/463030972?adppopup=true>
- p. Stephen Hawking In Paris—On March 03th In Paris, France Nachrichtenfoto—Getty Images. (n.d.). Retrieved September 16, 2021, from <https://www.gettyimages.ch/detail/nachrichtenfoto/stephen-hawking-in-paris-on-march-03th-in-paris-france-nachrichtenfoto/113418360>
- q. Stephen Hawking makes an appearance to show support for the Breathe... (n.d.). Getty Images. Retrieved September 16, 2021, from <https://www.gettyimages.ch/detail/nachrichtenfoto/stephen-hawking-makes-an-appearance-to-show-support-nachrichtenfoto/167803972>
- r. Stephen Hawking Nachrichtenfoto—Getty Images. (n.d.). Retrieved September 16, 2021, from <https://www.gettyimages.ch/detail/nachrichtenfoto/stephen-hawking-nachrichtenfoto/85864668>
- s. Theoretical physicist and author Stephen Hawking poses for a portrait... Nachrichtenfoto—Getty Images. (n.d.). Retrieved September 16, 2021, from <https://www.gettyimages.ch/detail/nachrichtenfoto/theoretical-physicist-and-author-stephen-hawking-poses-nachrichtenfoto/84146276>
- t. Theoretical Physicist Professor Stephen Hawking sits on stage ahead... Nachrichtenfoto—Getty Images. (n.d.). Retrieved September 16, 2021, from <https://www.gettyimages.ch/detail/nachrichtenfoto/theoretical-physicist-professor-stephen-hawking-sits-nachrichtenfoto/501557552>
- u. World-renowned physicist Stephen Hawking looks at the Bombay city... (n.d.). Getty Images. Retrieved September 16, 2021, from <https://www.gettyimages.ch/detail/nachrichtenfoto/world-renowned-physicist-stephen-hawking-looks-at-the-nachrichtenfoto/51343719>
- v. YjAi3RG.jpeg (1642 × 2048). (n.d.). Retrieved September 16, 2021, from <https://i.imgur.com/yjAi3RG.jpeg>
- w. 04.jpg (1100 × 1667). (n.d.). Retrieved September 16, 2021, from <https://cdn.cnn.com/cnn/interactive/2018/03/world/stephen-hawking-cnnphotos/media/04.jpg>